

# African Horse Sickness

**Author:** Dr Melvyn Quan

**Adapted from:** Coetzer, J.A.W and Guthrie, A.J. 2004. African horse sickness, in *Infectious diseases of livestock*, edited by J.A.W. Coetzer & R.C. Tustin. Oxford University Press, Cape Town, 2: 1231-1264

Licensed under a [Creative Commons Attribution license](#). 

## DIAGNOSIS AND DIFFERENTIAL DIAGNOSIS

---

### Clinical signs and pathology

Four clinical forms of AHS have been described – the “dunkop” or pulmonary, “dikkop” or cardiac, mixed and horse sickness fever forms.

#### “Dunkop” or pulmonary form

This form of the disease occurs commonly when AHSV infects fully susceptible horses, notably foals that have lost their passively acquired immunity. It is the form usually seen in dogs.

Following the incubation period, a fever may be the only sign for one or two days, with the rectal temperature reaching 41°C or sometimes higher. The characteristic clinical signs in this form of AHS are severe dyspnoea, paroxysms of coughing, and sometimes, discharge of large quantities of frothy, serofibrinous fluid from the nostrils.

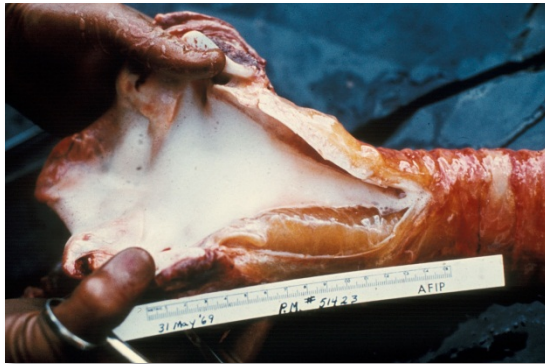


**Discharge of large quantities of frothy, serofibrinous fluid from the nostrils are seen in some horses with the pulmonary form of African horse sickness prior to death**

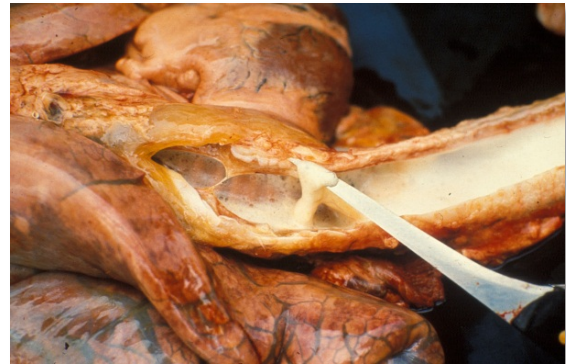In most cases the discharge from the nose only appears after death. The appetite of affected animals remains good in spite of the high fever and respiratory distress. Sometimes the animal may take a mouthful of hay without chewing it. The onset of dyspnoea is generally very sudden, and death often occurs within a few hours of its appearance.

The prognosis for horses suffering from the “dunkop” form is extremely grave; less than five per cent recover. In recovering horses the fever gradually subsides but the breathing remains laboured for some days.

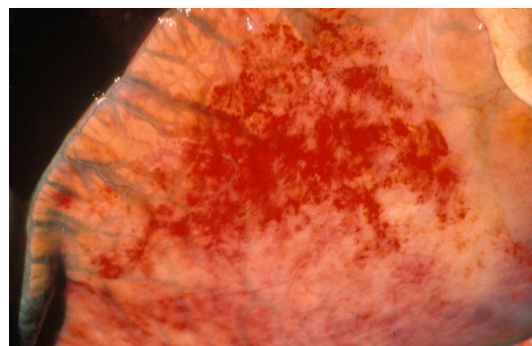
The most striking changes are severe oedema of the lungs and hydrothorax. Several litres of pale yellow fluid which may coagulate on exposure to air are found in the thoracic cavity.



**In the pulmonary form the trachea contains large amounts of froth**



**Froth and serofibrinous fluid which may be gelatinous in the trachea of a horse that died of the pulmonary form of the disease**



**Severe oedema of the interlobular septa of the lungs**

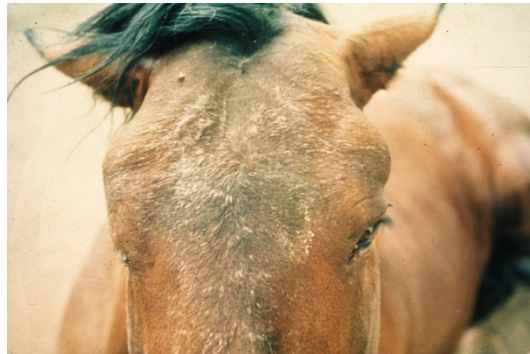Oedema of the subcutaneous and intermuscular tissues is usually absent or mild. The mediastinum, and often the loose connective tissue around major blood vessels in the thorax, oesophagus, trachea and thymus, may also be oedematous.

Hydropericardium is rare in this form of the disease. Epi- and endocardial haemorrhages of varying size (particularly severe in the left ventricle), sometimes accompanied by slight oedema of the fat in the coronary grooves and of the atrioventricular valves, may be evident.

Marked diffuse congestion of the mucosa of the glandular part of the stomach is a consistent finding. This may be accompanied by patchy congestion and petechiation of the serosa and, sometimes, of the mucosa of the intestine. The liver may be slightly enlarged and congested, and its lobulation slightly more distinct than normal. There is usually some degree of ascites.

### **“Dikkop” or cardiac form**

This form of AHS is characterized by subcutaneous oedema of the head and neck, and particularly the supraorbital fossae.

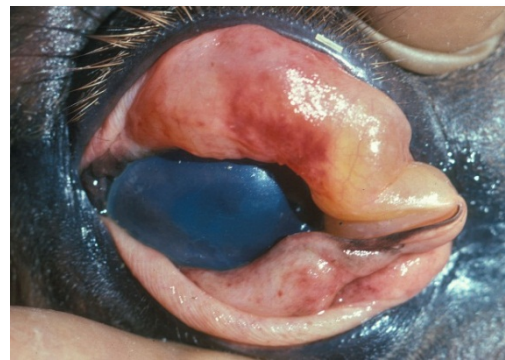

**Facial swelling and oedema of the supraorbital fossae**

The oedema usually appears late in the course of the disease, but if it appears early, the condition is more serious, more acute and with a higher rate of mortality. In severe cases, there may be oedema of the eyelids, lips, cheeks, tongue, intermandibular space, and sometimes also the neck, chest and shoulders, but usually not the lower parts of the legs (i.e. below the elbow or stifle joints).



**Oedema of the supraorbital fossa and eye lids**



**Severe oedema of the eyelids in a horse suffering from African horse sickness**

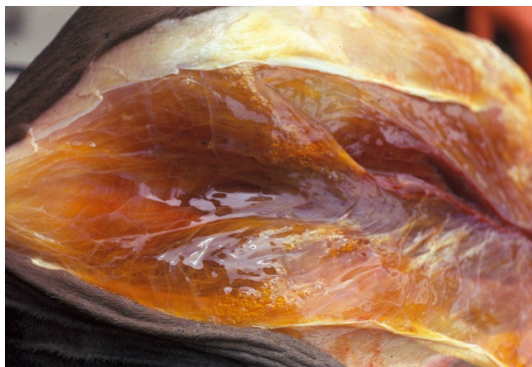

As the oedema worsens, dyspnoea and cyanosis may supervene.

Fever peaks at a later stage in the course of the disease than in the “dunkop” form, and may remain high for three to six days before declining. Some animals will only develop a very mild fever. Some animals may lie down repeatedly or are restless when standing, and frequently paw the ground with their front feet as a result of severe colic. Interference or difficulty in swallowing as a result of paralysis of the oesophagus may be a complication, particularly in those cases where there is severe oedema of the head.

The “dikkop” form of AHS is always more protracted and milder than the “dunkop” form, with a mortality rate of about 50 per cent. Death usually occurs within four to eight days of the onset of the febrile reaction. Unfavourable prognostic signs are petechiae in the mucosa of the conjunctivae and mouth, on the ventral aspect of the tongue. These, if they occur, are evident shortly before death.

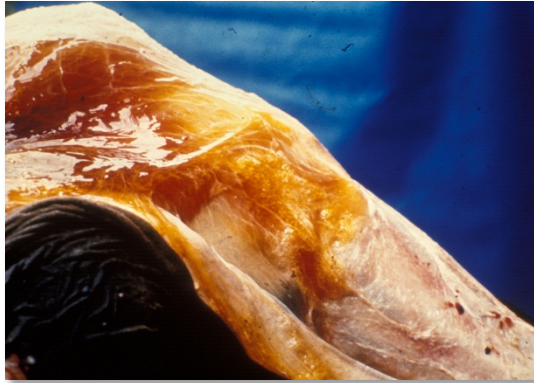The most characteristic pathological change is yellowish gelatinous oedema of the subcutaneous and intermuscular connective tissues of the head and neck.



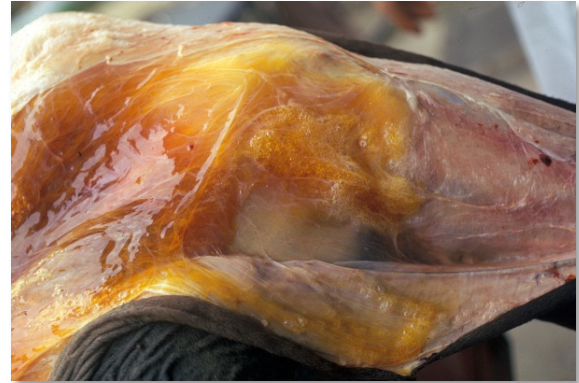**Severe oedema of the intermuscular connective tissue**



**Yellowish gelatinous oedema of the subcutaneous and intermuscular connective tissue**



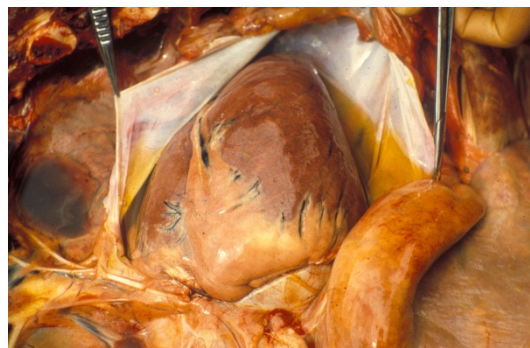**Yellowish gelatinous oedema of the subcutaneous tissues**



**Severe oedema of the intermuscular connective tissues**

In severe cases this extends to the back, shoulders and chest. The oedema is particularly severe around the ligamentum nuchae.

Lesions similar to, but more severe than those described for the “dunkop” form, are found in the heart. Pale greyish blanched areas of varying size may very rarely be noticed in the myocardium. Severe hydropericardium is almost invariably present.



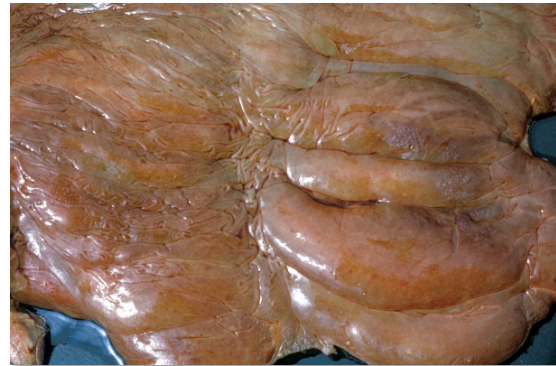
**Hydropericardium**

The lungs are usually normal or slightly congested, and only slightly oedematous. The thoracic cavity seldom contains an excess of fluid. Many lymph nodes are swollen and oedematous but the spleen is occasionally only slightly enlarged. The liver is engorged and its lobulation distinct. There is usually mild nephrosis.

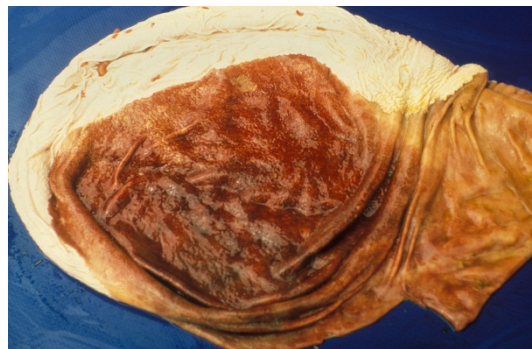
Lesions in the gastrointestinal tract are similar to, but more severe than, those found in the “dunkop” form. In cases which manifest severe paralysis of the oesophagus, the organ is distended with a variable amount of compressed food. Moderate to severe oedema, congestion and petechiation of the mucosa of the caecum, colon and rectum are regular findings.



**Oedema, congestion and petechiation of the intestines**



**Severe oedema and petechiation of the mucosa of the large intestine**



**Severe diffuse congestion of the glandular part of the stomach**

### **Mixed form**

Although this is the most common form of AHS it is very rarely diagnosed as such clinically; one of the other preceding forms predominates and this is reflected in the diagnosis. It is only during necropsy when lesions of both the “pulmonary” and “cardiac” forms are observed that the diagnosis is made.

Horses affected by this form may show signs either of respiratory distress followed by oedematous swellings or, initially, of the “dikkop” form before suddenly developing respiratory distress from which they may die. The mortality rate in horses affected by this form of the disease is approximately 70 per cent. Death usually follows three to six days after the onset of the febrile reaction.

### **Horse sickness fever**

This form usually occurs in horses immune to one or more serotypes of AHSV which become infected with a heterologous serotype against which there is some cross protection. It also occurs in species such as donkeys and zebras which are resistant to the development of clinical disease.

Horse sickness fever is a very mild form of the disease and is frequently not diagnosed clinically. The most characteristic finding is a rise of the rectal temperature (39 to 40 °C) lasting one to six days followed by a drop in temperature to normal, and recovery. Some horses may show partial loss of appetite, congestion of the conjunctivae, slightly laboured breathing, and increased heart rate, but these signs are transient.



## Laboratory confirmation

The epidemiology, clinical signs and gross lesions of AHS are often sufficiently specific to allow a provisional diagnosis of the disease to be made. To confirm the diagnosis, the virus should be isolated from blood collected, preferably in heparin-containing tubes, during the febrile stage of the disease or from specimens of the lungs, spleen and lymph nodes collected at necropsy and kept at 4 °C. In fatal cases high levels of infectivity are found in the lungs, spleen and lymph nodes. Virus isolation may be achieved by the use of a variety of cell cultures (e.g. BHK-21, VERO, monkey stable), by intracerebral inoculation of suckling mice or by intravenous inoculation of embryonated hens' eggs. When heparin is not available, blood collected in chelating agents such as Na-EDTA should be diluted five to ten fold to prevent detachment of the monolayer of cell cultures.

Virus isolates are identified by group-specific tests such as complement fixation (CF), agar gel immunodiffusion (AGID), direct and indirect immunofluorescence (IFA) or enzyme-linked immunosorbent assay (ELISA). Serotyping of AHS virus isolates is performed using virus neutralization (VN) tests employing type-specific antisera. Virus neutralization tests may be conducted in mice or various cell cultures e.g. plaque neutralization. Antibody to AHSV can be detected by utilizing CF, AGID, IFA, VN and ELISA tests.

In horses that have recovered from the disease, high CF antibody titres indicate infection with the virus within the previous few months. Antibodies detectable by VN tests and ELISA persist for a number of years.

A number of conventional reverse transcription polymerase chain reaction (RT-PCR) assays and real-time reverse transcription PCR assays have been developed for the detection of AHSV and to differentiate between the serotypes of AHSV. Genomic probes can also be developed and applied for *in situ* hybridization in tissues. Immunohistochemical staining methods have also been used successfully to determine the localization of AHS antigen within various tissues. The advantages of these new approaches are that they have the potential to be rapid, sensitive and versatile, and they may supplement or replace some of the older conventional methods. Furthermore, they can be applied to specimens from clinical cases that do not contain live virus. Immunohistochemical staining can be applied to tissues that have been preserved in 10% buffered formalin, which is an advantage if it is not possible for the samples to reach the laboratory rapidly.

## Differential diagnosis

It is not possible to differentiate the AHS fever form of the disease from the early febrile stages of other forms of AHS, or from the early febrile stages of many other equine infectious diseases.

The clinical signs and lesions of AHS may be confused with those of equine encephalosis. As many of the epidemiological features of the two diseases are similar, they may occur simultaneously in South Africa and possibly also in other regions in southern Africa. Horses manifesting swelling of the eyelids, supraorbital fossae or of the entire head as a result of equine encephalosis cannot be differentiated clinically from the “dikkop” form of AHS. However, the mortality rate of AHS is much higher than is that of equine encephalosis. Virus isolation and identification or serological tests on paired serum samples are essential to confirm either diagnosis.

Although the lesions of AHS at necropsy are fairly characteristic, the disseminated small haemorrhages and the oedema found in some parts of the body that are associated with the “dikkop” form of AHS may be very similar to those found in cases of purpura haemorrhagica and equine viral arteritis. In horses affected by these conditions, subcutaneous oedema often occurs ventral to the elbow and stifle joints, as well as in other locations, while in those suffering from AHS it does not occur below these joints. In purpura haemorrhagica, oedema and haemorrhages tend to be more numerous, widespread and severe than in AHS.

The early stages of piroplasmiasis, when *Babesia/Theileria* parasites may be difficult to demonstrate in blood smears, are occasionally confused with AHS. AHS may also be complicated by piroplasmiasis, and in such cases ventral oedema may be severe.